



The Effect of Bladder Volume on Three-dimensional Vaginal Cuff Brachytherapy Planning

Sümerya Duru BİRGİ,¹ Ozan Cem GÜLER,² Yunus BABAYİĞİT,¹ Yakup ARSLAN,¹ Serap AKYÜREK¹

¹Department of Radiation Oncology, Ankara University Faculty of Medicine, Ankara-Türkiye

²Department of Radiation Oncology, Adana Başkent University Hospital, Adana-Türkiye

OBJECTIVE

We aimed to determine the effect of a Foley catheter on bladder fullness and the changes in the doses received by other critical organs (OAR) and target volumes during high-dose rate vaginal cuff brachytherapy (HDR-VBT) with an empty bladder.

METHODS

Twenty patients with a diagnosis of endometrial or cervical cancer underwent post-operative three-dimensional HDR-VBT between January 2020 and May 2021 and were examined dosimetrically. After the evacuation of the urine, two simulation CT scans and plans were performed with and without inserting a Foley catheter. For both plans, the volumes and doses of HRCTV and each critical organ were recorded separately.

RESULTS

The median age of the patients was 60 years (35–79). HDR-VBT was applied to 16 patients with endometrial cancer and 4 patients with cervical cancer diagnosis. Median 50.4 Gy (45–50.4 Gy) external RT was administered to 12 patients with a total of 15 Gy BRT boost in 3 fractions. A total of 27.5 Gy HDR-VBT in 5 fractions were administered to 8 endometrial cancer patients. No significant difference was found regarding target and critical organ volumes between the two plans with or without a Foley catheter. Also, no statistically significant difference was detected in terms of target doses such as D90, D95, and D98 of HRCTV and D0.1, D1, D2cc, and mean doses of critical organs.

CONCLUSION

It seems simulating and treating the patient by just emptying the urine and using the decay and treat method is sufficient in terms of OAR and HRCTV dose limits.

Keywords: Bladder; brachytherapy; cervical cancer; endometrial cancer.

Copyright © 2024, Turkish Society for Radiation Oncology

INTRODUCTION

High-dose rate vaginal cuff brachytherapy (HDR-VBT), either administered independently or in conjunction with external beam radiotherapy (EBRT), constitutes a

frequently employed treatment modality following hysterectomy for the management of gynecologic malignancies.[1–5] This treatment regimen is typically applied to patients diagnosed with endometrial carcinoma in pathological Stages I-III disease in combination with EBRT

This study was presented as poster presentation at ESTRO 2022, in Copenhagen, in 6-10 May 2022.

Received: November 04, 2023

Accepted: November 30, 2023

Online: December 10, 2023

Accessible online at:

www.onkder.org

Dr. Sümerya Duru BİRGİ

Ankara Üniversitesi Tıp Fakültesi,

Radyasyon Onkolojisi Anabilim Dalı,

Ankara-Türkiye

E-mail: sumeryaduru03@hotmail.com



for those with more advanced disease or alone in early stage with low-grade histology.[6,7] In light of the affirmative outcomes from previous studies, the utilization of HDR-VBT has obtained a notable increase.[8–12]

With the development of imaging technology, especially the utilization of computed tomography (CT), there has been substantial interest in implementing three-dimensional (3D) treatment planning for intracavitary brachytherapy in recent years. Currently, approximately 80% of treatment plans are structured in 3D format, with up to 75% exclusively executed during the initial application.[13] The guidelines provided by the American Brachytherapy Society (ABS) recommend a customized treatment plan established once for each patient and applied consistently for all treatment sessions because customizing treatment plans for every treatment session would be mostly time-consuming, incurring additional technical expenses, and likely not yield discernible improvements in patient outcomes.[14–16] Therefore, fixed geometry applicator using assumes to prevent potential variations in applicator position between treatment sessions, or radiographs or other measures are taken to ensure that the applicator remains in the same position within the vagina and relation to the bladder and rectum for each application is recommended. However, the necessity for routinely calculating bladder and rectal doses during the administration of VBT alone has been a subject of inquiry. This is due to the relatively low dose delivered to normal tissues and the overall low treatment-related complications. In ABS, guideline-specific parameters and standardized bladder filling conditions for patients undergoing VBT were not definitively established. Furthermore, the optimal indicators for quantifying the radiation dose to the bladder during VBT are not clear.

Numerous studies have conducted assessments of 3D conformal treatment plans in patients diagnosed with cervical and endometrial cancers.[17–20] These studies involved the dosimetric comparison of some features between 2D and 3D plans. The manipulation of internal anatomical parameters has been the subject of an extensive investigation to gauge its influence on the radiation dose administered to both target and normal tissue during VBT. The effect of bladder fullness on dose distribution has been thoroughly examined within the context of both cervical and endometrial cancer, yielding conflicting results.[20–24] Despite the available data on bladder fullness during BRT with intact uterus, the delivery of BRT through a vaginal cylinder remains a topic infrequently addressed in 3D image-based dosimetric studies.[25,26] In a prospective study,

Stewart et al.[27] found that augmenting bladder filling heightened the maximum bladder dose and the volume of the bladder receiving $\geq 70\%$ of the prescribed dose. Nevertheless, this maneuver displaced the nearest bowel away from the vaginal cylinder. Another study by Hung et al.[28] illustrated that bladder filling, while effective in reducing radiation exposure to the small bowel, did not adversely impact the dose to the bladder, rectum, or sigmoid colon. Additionally, Kobzda et al.[24] observed that the dose to the empty bladder was lower compared to the distended bladder, and the doses to the intestine rose comparatively when the bladder was empty as opposed to when it was full. Hoskin et al.[29] employed urinary catheterization to ensure consistent bladder-filling states before VBT. A comparison between a full bladder and an empty bladder has shown that bladder fullness reduces D50% values of the bladder and decreases the dose to the small intestine. Despite the multifaceted considerations pertaining to VBT treatment planning, a definitive correlation between radiation dose and clinical outcomes remains unclear.

Consequently, there has been a lack of standardization regarding bladder filling and dose estimation, which hinders the establishment of routine clinical practices in 3D treatment planning. The utilization of 3D treatment with either an empty or full bladder varies among radiation therapy centers. It is considered appropriate to simulate treatment planning for vaginal cuff brachytherapy with an empty bladder and rectum. Nevertheless, the practice of employing a Foley catheter to empty the bladder in each treatment fraction can potentially impact the risk of infection, treatment compliance, and the overall quality of life for patients.

In this study, our primary objective was to ascertain the influence of a Foley catheter on bladder fullness and its subsequent effects on the doses received by critical organs and target volumes in post-operative endometrial or cervical cancer patients undergoing vaginal cuff brachytherapy with an empty bladder.

MATERIALS AND METHODS

Patients

A dosimetric examination was conducted on twenty patients diagnosed with post-operative endometrial or cervical cancer. These patients had undergone three-dimensional vaginal HDR-BRT using a multi-channel cylinder applicator between January 2020 and May 2021. All patients had previously undergone total abdominal hysterectomy, and a subset of them had received EBRT

Table 1 Patient and tumor characteristics

	n	%		n	%
Age			Histology		
≤60 years	10	50	Adenocancer	13	65
>60 years	10	50	Squamous cell carcinoma	4	20
ECOG performance			Serous carcinoma	1	5
0	8	40	Uterine carcinosarcoma	2	10
1	11	55	Tumor grade		
2	1	5	Grade 1	3	15
Comorbidity			Grade 2	10	50
Yes	15	75	Grade 3	4	20
No	5	25	Unknown	3	15
Body mass index			Treatment Schedule		
<30	5	25	ERT+BRT	12	60
30–35	11	55	BRT alone	8	40
>35	4	20	ERT dose		
Diagnosis			45 Gy	1	8
Endometrium	16	80	50.4 Gy	11	92
Cervix	4	20	BRT dose		
FIGO 2009 stage			3*5Gy	12	60
1a	5	25	5*5 Gy	8	40
1b	5	25	Chemotherapy		
2	4	20	Yes	7	35
3c1	3	15	No	13	65
3c2	3	15			

ECOG: Eastern Cooperative Oncology Group (ECOG) Performance Score; FIGO: The International Federation of Gynecology and Obstetrics Staging Status; ERT: External beam radiotherapy; BRT: Brachytherapy

before BRT treatment. The characteristics of the patients are presented in Table 1. Ethical approval for this study was obtained from the institutional review board. This study has been conducted in accordance with the principles outlined in the Helsinki Declaration.

Simulation and Insertions

Before the delivery of brachytherapy (BRT), a thorough gynecologic examination was conducted to evaluate the condition of the vaginal vault and to ascertain the appropriate applicator diameter. To prepare for the procedure, patients were required to undergo a laxative or enema regimen to empty the intestinal contents. Subsequently, after voiding the bladder, two simulation CT scans were performed: first, without a Foley catheter and after then, with the insertion of a 16-French Foley catheter with 7 mL of saline filling the balloon.

Intracavitary BRT was carried out using plastic multichannel cylinder applicators that were compatible with CT imaging, and these applicators were selected to accommodate cylinders customized to suit each patient's anatomy in diameters ranging from 2.5 to 3.5 cm. The cylinder was sheathed with a lubricated condom and positioned anatomically to prevent any

pressure on the bladder anteriorly or the rectum posteriorly. The applicator was securely fastened in place using a universal applicator clamping device located beneath the patient. Consistently, the same applicators were used throughout the treatment course. Moreover, before each BRT session, the applicator's position was verified through radiographs to ensure it remained in the same location as during the initial application.

The CT simulation was performed to cover the entire length of the vaginal applicator, scanning the region of interest in the pelvic region from the L4/L5 interface to the lower border of the ischial tuberosity. A CT scan with 2.5-mm thick slices was carried out adhering to the established departmental protocol. Notably, no oral or intravenous contrast agents were employed during the planning CT. The patients were positioned in the supine posture with their legs fully extended during both simulation and treatment procedures. During planning, target volumes and critical organs such as the rectum, bladder, sigmoid colon, and small bowel were outlined according to the relevant guidelines on the CT scan slices acquired for treatment planning. Each organ was contoured by outlining its entire structure. The rectum was defined as

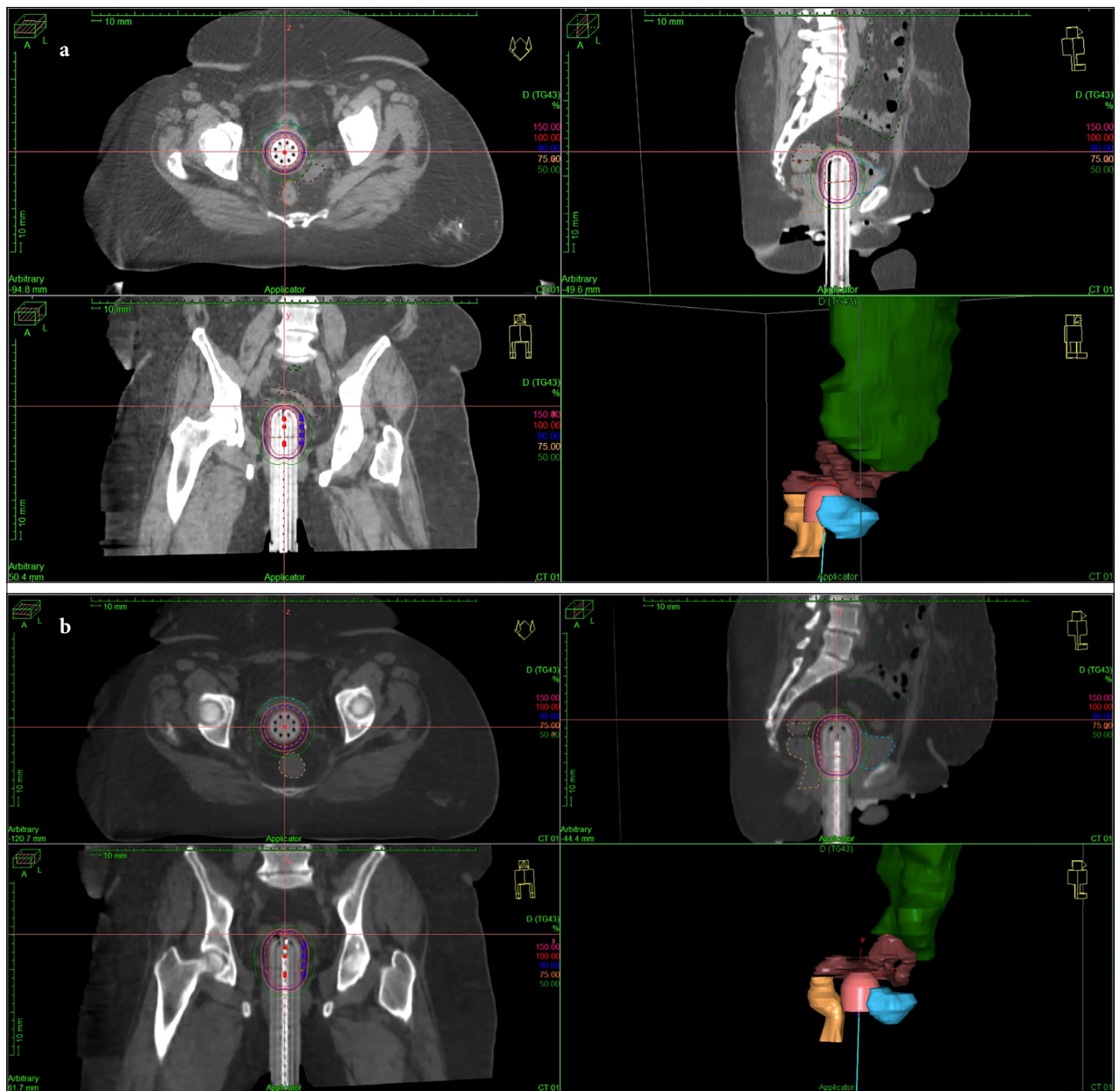


Fig. 1. Three dimensional HDR-VBT treatment plan of one endometrium cancer patient. (a) 3D-BRT plan with Foley catheter, (b) 3D-BRT plan without Foley catheter.
HDR-VBT: High-dose rate vaginal cuff brachytherapy; 3D-BRT: Three dimensional brachytherapy.

the colonic segment extending from the rectosigmoid junction to the anal verge. The sigmoid colon was characterized as the bowel section extending proximal to the rectum, marked by a transition to a vertical orientation. The designation of small bowel encompassed all individual loops of the intestines, excluding the rectum and sigmoid colon, up to the level of the inferior sacroiliac joints. This delineation included individual loops of the bowel as visualized during the CT simulation process.

Treatment Planning and Delivery

All patients received treatment using a Nucletron Flexitron model with an Iridium-192 source HDR afterloader, manufactured by ELEKTA Medical Systems in the UK. The treatment planning was performed using the Oncentra Brachy version 4.6.3 treatment planning system software. Multichannel vaginal cylinders were employed for all insertions to target the proximal one-third, approximately 3–5 cm of the vagina, adher-

ing to the recommendations of both ABS and Groupe Européen de Curiethérapie and European Society for Therapeutic Radiology and Oncology (GEC-ESTRO). [14,25,26] HDR irradiation with an iridium-192 source was prescribed to a depth of 0.5 cm from the surface of the cylinder. The dose per fraction ranged from 5 to 6 Gy for all patients. The treatment plans were optimized using the Inverse Planning Simulated Annealing technique to ensure the delivery of 100% of the prescribed dose to the designated prescription point. The treatment plan that was approved during the planning CT scan with the Foley catheter in place was transferred to the CT scan without the Foley catheter, and DVH parameters were assessed separately (Fig. 1a, b). For both plans, values such as D90, D95, and D98 for High-Risk Clinical Target Volume (HRCTV) were recorded. Additionally, the doses to critical organs, including the bladder, rectum, and sigmoid, were documented separately for volumes of 0.1 cc, 1 cc, and 2 cc. All treatment plans adhered to the GEC-ESTRO recommendations, ensuring that doses to 2 cc of the organs at risk other critical organs (OARs) met the criteria of D2cc for the rectum, sigmoid, and small bowel below 5 Gy and for the bladder below 7 Gy, respectively.

Statistical Analysis

Statistical analysis was performed using (SPSS v20.0; SPSS Inc., Chicago, IL, USA). The doses of the target volume (HRCTV) and critical organs were compared between the treatment plan without the Foley catheter and the decay-and-treat method plan with the inserted Foley catheter. Paired sample t-tests were performed to assess the significance of differences in volumes and doses between the brachytherapy (BRT) plans. Results are presented as mean values along with their standard deviations unless otherwise specified. The statistical significance was considered for $p < 0.05$.

RESULTS

The median age of the patients was 60 years (35–79). The median ECOG performance score was 1 (0–2) and 75% (n=15) had additional comorbidities. Half of the patients were obese, and the median body mass index (BMI) in all patients was 34 kg/m² (20–40). The features of patients are summarized in Table 1.

Vaginal cuff BRT was applied to 16 patients diagnosed with endometrial cancer and 4 patients with cervical cancer with SCC histology. Median 50.4 Gy (45–50.4 Gy) external RT was applied to 12 patients with a total of 15 Gy BRT boost in 3 fractions. A total

Table 2 Volumes of HRCTV and organs at risk

Parameter	Urinary catheter + cc±SD	Urinary catheter – cc±SD	p
Bladder volume	62.03±15.37	67.58±20.02	0.204
Rectum volume	66.60±23.33	68.02±19.10	0.673
Sigmoid volume	167.16 ±111.10	160.68±105.16	0.693
Intestine volume	1482.92±473.46	1525.32±463.18	0.607
HRCTV volume	61.99±35.72	63.89±33.49	0.192

HRCTV: High-Risk Clinical Target Volume; SD: Standard deviation

Table 3 Dosimetric analysis of HRCTV

Parameter	Urinary catheter + Gy/cc±SD	Urinary catheter – Gy/cc±SD	p
HRCTV 98	4.97±0.56	5.03±0.58	0.501
HRCTV 95	5.31±0.50	5.33±0.47	0.737
HRCTV 90	5.68±0.47	5.68±0.40	0.954
HRCTV mean	11.85±1.14	11.79±1.34	0.803

of 27.5 Gy HDR-BRT in 5 fractions was applied to 8 early-stage endometrial cancer patients.

Concerning DVH parameters volumes of HRCTV and organs at risk were summarized in Table 2. All critical organ doses were within limits and intestine doses were notably low. No significant difference was found between target and critical organ volumes when the DVH parameters of the plan with and without the Foley catheter were evaluated. In addition, the mean and specified cc volumes of OARS such as D0.1, D1, D2cc, and also mean and D90, D95, and D98 doses of HRCTV were summarized in Tables 3 and 4. No statistically significant difference was found between the two plans in terms of target and critical organ doses.

DISCUSSION

In our study, we observed no statistically significant differences between the BRT plans with or without the insertion of a Foley catheter in terms of the doses of organs at risk, including the bladder, rectum, sigmoid, and small bowel, as well as HRCTV doses.

The use of 3D VBT treatment planning, particularly concerning bladder filling and the optimal planning schedule, still lacks a consensus. There have been a limited number of studies investigating the impact of bladder distention on OAR doses in patients who have undergone hysterectomy and received HDR-VBT. In a

Table 4 Dosimetric analysis of organs at risk

Parameter	Urinary catheter + Gy/cc±SD	Urinary catheter – Gy/cc± SD	p
Bladder			
Bladder 2cc	4.44±0.65	4.42±0.49	0.889
Bladder 1cc	4.73±0.68	4.72±0.52	0.959
Bladder 0.1cc	5.38±0.78	5.41±0.56	0.800
Bladder mean	3.14±0.48	3.14±0.43	0.960
Rectum			
Rectum 2cc	4.70±0.52	4.80±0.37	0.276
Rectum 1cc	5.15±0.56	5.28±0.41	0.266
Rectum 0.1cc	6.10±0.74	6.30±0.63	0.263
Rectum mean	3.17±0.49	3.09±0.36	0.397
Sigmoid			
Sigmoid 2cc	3.55±0.99	3.48±0.77	0.656
Sigmoid 1cc	3.92±1.19	3.86±0.88	0.740
Sigmoid 0.1cc	4.76±1.60	4.69±1.11	0.789
Sigmoid mean	2.29±0.40	2.23±0.40	0.360
Intestine			
Intestine 2cc	1.47±0.75	1.46±0.84	0.869
Intestine 1cc	1.59±0.82	1.57±0.92	0.808
Intestine 0.1 cc	1.90±0.96	1.84±1.09	0.696
Intestine mean	0.93±0.91	0.86±0.94	0.310

study conducted by Hoskin et al.,[29] it was determined that infusing the bladder with 100 mL of liquid resulted in a significant 57.5% reduction in the exposure of the small bowel within the high-dose treatment region, as assessed on CT slices through the cranial-most dwell positions, compared to cases with a voided bladder. However, it is noteworthy that this study relied on 2D measurements of bladder height, and as such, volumetric parameters of the bladder were not considered, and doses to the sigmoid colon and small bowel were not evaluated. In contrast, Kobzda et al.[24] discovered that the dose to the empty bladder was lower than when the bladder was full (4.6 Gy, range: 3.1–5.6 Gy, vs. 4.9 Gy, range: 3.9–5.9 Gy; $p < 0.05$). Furthermore, the doses to the bowels increased proportionally when the bladder was empty compared to when it was full (4.6 Gy, range: 2.5–7.3 Gy, vs. 4.1 Gy, range: 1.3–5.7 Gy; $p < 0.05$).

The study by Hung et al.[28] explored the dosimetric impact of bladder distension in 3D treatment planning for post-operative gynecologic cancer patients undergoing vaginal brachytherapy. Their study found no statistically significant differences in rectum, sigmoid, or bladder dosimetry between treatments with an empty bladder (indwelling catheter) and a full bladder (180 mL of sterile water). However, they did observe a significant reduction in mean small bowel

D2cc and small bowel D50% when treating with a full bladder. As a result, they recommended the preference for vaginal cylinder brachytherapy with a distended bladder, citing the dosimetric advantage to the small bowel. In a prospective trial conducted by Stewart et al.,[27] they assessed radiation doses to normal tissues during VBT and studied the impact of non-invasive bladder filling on normal tissue dosimetry using CT imaging. Their findings revealed that both the volume and surface area of the bladder receiving radiation were significantly smaller when the bladder was empty compared to when it was full. Therefore, they suggested that, whenever feasible, patients undergoing HDR-VBT should be treated with an empty bladder. They highlighted the shift in focus from urinary catheterization, previously a common method for bladder emptying during low-dose rate VBT, to patient comfort and practicality in outpatient HDR treatments. Although their study did not assess the dosimetry of the sigmoid and small bowel, they reported a significant increase in the cylinder-to-bowel distance from 0.575 to 1.16 cm with an empty to full bladder. The study by Guler et al.[30] demonstrated that a combination of a distended bladder and an empty rectum before vaginal vault brachytherapy could lead to increased bladder doses, potentially resulting in lower doses to the sigmoid colon and small bowel. However, the impact of bladder distention on gastrointestinal and genitourinary toxicities remains uncertain. As a result, it may be adequate to implement appropriate bowel preparation before each therapeutic session, particularly in high-volume patient clinics, without the need for bladder distension. It is important to note that this concept is tentative and requires further validation through additional dosimetric and clinical investigations.

Our study had several limitations. First, the contouring of OARs on CT scans, particularly the rectum, sigmoid, and small bowel was challenging to distinguish the borders due to the lack of oral contrast. To minimize variability and standardize volume delineation, a single dosimetric contoured all OARs. Additionally, the study was limited by the relatively small number of patients analyzed, which restricts the generalizability of the results. Finally, it is essential to acknowledge that this investigation was designed as a dosimetric study and did not incorporate clinical outcomes.

CONCLUSION

In conclusion, our study suggests that, for vaginal cuff brachytherapy, an empty bladder appears to be suitable

in terms of both critical organ doses and HRCTV coverage. Additionally, our study revealed that the doses to the small intestine were notably low. It implies simply voiding the bladder before treatment sessions to be sufficient and the use of a Foley catheter for bladder emptying may not be necessary. However, it is important to note that this study was primarily designed as a dosimetric analysis. To establish its clinical implications more conclusively, further studies are needed to support and validate these findings.

Peer-review: Externally peer-reviewed.

Conflict of Interest: All authors declared no conflict of interest.

Ethics Committee Approval: The study was approved by the Ankara University Human Research Ethics Committee (no: İ07-505-23, date: 21/08/2023).

Financial Support: None declared.

Authorship contributions: Concept – S.D.B., Y.B.; Design – S.A., Y.A.; Supervision – S.A., S.D.B.; Funding – S.D.B., O.C.G.; Materials – Y.B., Y.A.; Data collection and/or processing – Y.B., Y.A.; Data analysis and/or interpretation – O.C.G., Y.B.; Literature search – S.D.B., O.C.G.; Writing – S.A., S.D.B.; Critical review – S.A., O.C.G.

REFERENCES

- Klopp A, Smith BD, Alektiar K, Cabrera A, Damato AL, Erickson B, et al. The role of postoperative radiation therapy for endometrial cancer: Executive summary of an American Society for Radiation Oncology evidence-based guideline. *Pract Radiat Oncol* 2014;4(3):137–44.
- Chen MF, Tseng CJ, Tseng CC, Kuo YC, Yu CY, Chen WC. Clinical outcome in posthysterectomy cervical cancer patients treated with concurrent cisplatin and intensity-modulated pelvic radiotherapy: Comparison with conventional radiotherapy. *Int J Radiat Oncol Biol Phys* 2007;67(5):1438–44.
- Chadha M. Gynecologic brachytherapy-II: Intravaginal brachytherapy for carcinoma of the endometrium. *Semin Radiat Oncol* 2002;12(1):53–61.
- Southcott BM. Carcinoma of the endometrium. *Drugs* 2001;61(10):1395–405.
- Ogino I, Kitamura T, Okamoto N, Nakayama H, Matsubara S. High dose rate intracavitary brachytherapy for recurrent or residual lesions in the vaginal cuff: Results in post-hysterectomy patients with carcinoma of the cervix. *Int J Gynecol Cancer* 2001;11(1):61–8.
- Solhjem MC, Petersen IA, Haddock MG. Vaginal brachytherapy alone is sufficient adjuvant treatment of surgical stage I endometrial cancer. *Int J Radiat Oncol Biol Phys* 2005;62(5):1379–84.
- Nori D, Merimsky O, Batata M, Caputo T. Postoperative high dose-rate intravaginal brachytherapy combined with external irradiation for early stage endometrial cancer: A long-term follow-up. *Int J Radiat Oncol Biol Phys* 1994;30(4):831–7.
- Keys HM, Roberts JA, Brunetto VL, Zaino RJ, Spirtos NM, Bloss JD, et al.; Gynecologic Oncology Group. A phase III trial of surgery with or without adjunctive external pelvic radiation therapy in intermediate risk endometrial adenocarcinoma: A Gynecologic Oncology Group study. *Gynecol Oncol* 2004;92(3):744–51.
- Scholten AN, van Putten WL, Beerman H, Smit VT, Koper PC, Lybeert ML, et al.; PORTEC Study Group. Postoperative radiotherapy for stage 1 endometrial carcinoma: Long-term outcome of the randomized PORTEC trial with central pathology review. *Int J Radiat Oncol Biol Phys* 2005;63(3):834–8.
- Alektiar KM, Venkatraman E, Chi DS, Barakat RR. Intravaginal brachytherapy alone for intermediate-risk endometrial cancer. *Int J Radiat Oncol Biol Phys* 2005;62(1):111–7.
- Nout RA, Putter H, Jürgenliemk-Schulz IM, Jobsen JJ, Lutgens LC, van der Steen-Banasik EM, et al. Quality of life after pelvic radiotherapy or vaginal brachytherapy for endometrial cancer: First results of the randomized PORTEC-2 trial. *J Clin Oncol* 2009;27(21):3547–56.
- Nout RA, Smit VT, Putter H, Jürgenliemk-Schulz IM, Jobsen JJ, Lutgens LC, et al.; PORTEC Study Group. Vaginal brachytherapy versus pelvic external beam radiotherapy for patients with endometrial cancer of high-intermediate risk (PORTEC-2): An open-label, non-inferiority, randomised trial. *Lancet* 2010;375(9717):816–23.
- Harkenrider MM, Grover S, Erickson BA, Viswanathan AN, Small C, Kliethermes S, et al. Vaginal brachytherapy for postoperative endometrial cancer: 2014 Survey of the American Brachytherapy Society. *Brachytherapy* 2016;15(1):23–9.
- Small W Jr, Beriwal S, Demanes DJ, Dusenbery KE, Eifel P, Erickson B, et al.; American Brachytherapy Society. American Brachytherapy Society consensus guidelines for adjuvant vaginal cuff brachytherapy after hysterectomy. *Brachytherapy* 2012;11(1):58–67.
- Corso CD, Jarrio C, Nunnery EW, Ali AN, Ghavidel S, Rossi PJ, et al. Dosimetric and cost comparison of first fraction imaging versus fractional re-imaging on critical organ dose in vaginal cuff brachytherapy. *Pract Radiat Oncol* 2013;3(4):256–62.
- Holloway CL, Macklin EA, Cormack RA, Viswanathan AN. Should the organs at risk be contoured in vaginal cuff brachytherapy? *Brachytherapy* 2011;10(4):313–7.
- Kim H, Kim H, Houser C, Beriwal S. Is there any advantage to three-dimensional planning for vaginal cuff brachytherapy? *Brachytherapy* 2012;11(5):398–401.

18. Onal C, Arslan G, Topkan E, Pehlivan B, Yavuz M, Oymak E, et al. Comparison of conventional and CT-based planning for intracavitary brachytherapy for cervical cancer: Target volume coverage and organs at risk doses. *J Exp Clin Cancer Res* 2009;28(1):95.
19. Kim RY, Shen S, Duan J. Image-based three-dimensional treatment planning of intracavitary brachytherapy for cancer of the cervix: Dose-volume histograms of the bladder, rectum, sigmoid colon, and small bowel. *Brachytherapy* 2007;6(3):187–94.
20. Caon J, Holloway C, Dubash R, Yuen C, Aquino-Parsons C. Evaluating adjacent organ radiation doses from postoperative intracavitary vaginal vault brachytherapy for endometrial cancer. *Brachytherapy* 2014;13(1):94–9.
21. Cengiz M, Grdalli S, Selek U, Yildiz F, Saglam Y, Ozyar E, et al. Effect of bladder distension on dose distribution of intracavitary brachytherapy for cervical cancer: Three-dimensional computed tomography plan evaluation. *Int J Radiat Oncol Biol Phys* 2008;70(2):464–8.
22. Sun LM, Huang HY, Huang EY, Wang CJ, Ko SF, Lin H, et al. A prospective study to assess the bladder distension effects on dosimetry in intracavitary brachytherapy of cervical cancer via computed tomography-assisted techniques. *Radiother Oncol* 2005;77(1):77–82.
23. Kim RY, Shen S, Lin HY, Spencer SA, De Los Santos J. Effects of bladder distension on organs at risk in 3D image-based planning of intracavitary brachytherapy for cervical cancer. *Int J Radiat Oncol Biol Phys* 2010;76(2):485–9.
24. Kobzda JD, Cikowska-Wozniak E, Michalska M, Makarewicz R. Three-dimensional dosimetry of the full and empty bladder in high dose rate vaginal cuff brachytherapy. *Int J Gynecol Cancer* 2014;24(5):923–7.
25. Haie-Meder C, Ptter R, Van Limbergen E, Briot E, De Brabandere M, Dimopoulos J, et al.; Gynaecological (GYN) GEC-ESTRO Working Group. Recommendations from Gynaecological (GYN) GEC-ESTRO Working Group (I): Concepts and terms in 3D image based 3D treatment planning in cervix cancer brachytherapy with emphasis on MRI assessment of GTV and CTV. *Radiother Oncol* 2005;74(3):235–45.
26. Ptter R, Haie-Meder C, Van Limbergen E, Barillot I, De Brabandere M, Dimopoulos J, et al.; GEC ESTRO Working Group. Recommendations from gynaecological (GYN) GEC ESTRO working group (II): Concepts and terms in 3D image-based treatment planning in cervix cancer brachytherapy-3D dose volume parameters and aspects of 3D image-based anatomy, radiation physics, radiobiology. *Radiother Oncol* 2006;78(1):67–77.
27. Stewart AJ, Cormack RA, Lee H, Xiong L, Hansen JL, O'Farrell DA, et al. Prospective clinical trial of bladder filling and three-dimensional dosimetry in high-dose-rate vaginal cuff brachytherapy. *Int J Radiat Oncol Biol Phys* 2008;72(3):843–8.
28. Hung J, Shen S, De Los Santos JF, Kim RY. Image-based 3D treatment planning for vaginal cylinder brachytherapy: Dosimetric effects of bladder filling on organs at risk. *Int J Radiat Oncol Biol Phys* 2012;83(3):980–5.
29. Hoskin PJ, Vidler K. Vaginal vault brachytherapy: The effect of varying bladder volumes on normal tissue dosimetry. *Br J Radiol* 2000;73(872):864–6.
30. Guler OC, Onal C, Acibuci I. Effects of bladder distension on dose distribution of vaginal vault brachytherapy in patients with endometrial cancer. *J Contemp Brachytherapy* 2015;6(4):371–6.