



# Severe Proptosis due to Myeloid Sarcoma, Dramatic Recovery with Chemotherapy: A Case Report

**Ayşe ÖZKAN KARAGENÇ, Esra ARSLANTAŞ, Hüseyin Avni SOLGUN, Ali AYÇİÇEK**

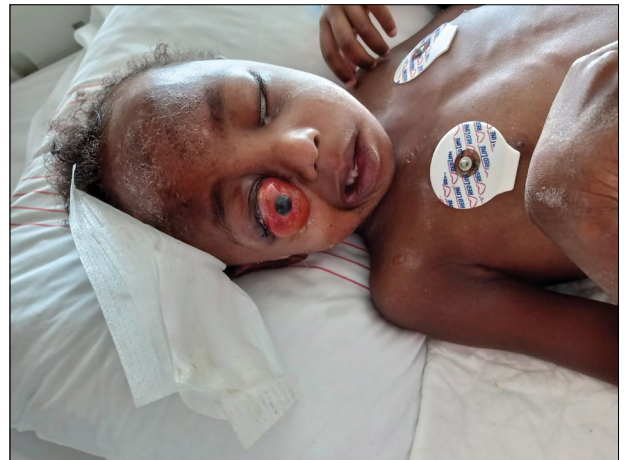Department of Pediatric Hematology and Oncology, University of Health Sciences, Başakşehir Çam and Sakura City Hospital, İstanbul-Türkiye

## Dear Editor,

Acute leukemias constitute 25–30% of childhood malignant tumors. Acute myeloid leukemia (AML) is seen in 20% of childhood leukemia.[1] Extramedullary involvement is seen in 10–20% of AML. Gingival hypertrophy, lymphadenopathy, and skin involvement are the most common sites of extramedullary involvement, while orbital involvement and paraspinal mass are other common sites.[2]

A 7-year-old girl was sent from Somalia for proptosis. The patient was healthy until 5 months ago. Inguinal and axillary lymphadenopathy and hepatosplenomegaly were detected in the hospital, he went to due to fever, loss of appetite, and weight loss. Pancytopenia was observed in blood tests and left facial palsy developed in the follow-up. In addition to supportive and transfusion treatments, meningitis treatment was applied. A gradually growing mass developed in his right eye, he had contractions and was followed up in the intensive care unit for a while.

When the patient came to our center, he was cachectic, severe proptosis, chemosis, and advanced keratopathy were present in the right eye (Fig. 1). In blood tests, hemoglobin: 7.2 g/dl, mean corpuscular volume: 83.5 fL, white blood cell: 64,700/mm<sup>3</sup>, neutrophil: 45,300/mm<sup>3</sup>, platelet: 7000/mm<sup>3</sup>, lactic dehydrogenase: 1898 U/L, uric acid: 7.74 mg/dl, creatinine 1.17 mg/dL, erythrocyte sedimentation rate: 61/H. Cranial and orbital magnetic resonance imaging showed a concentrically enlarged mass lesion measuring approximately 3.5×3.5×2 cm, with contrast-enhancement in the anterior right pre-orbital and periorbital region (Fig. 2).



**Fig. 1.** The image of the patient with right orbital myeloid sarcoma at the first admission in the intensive care unit.

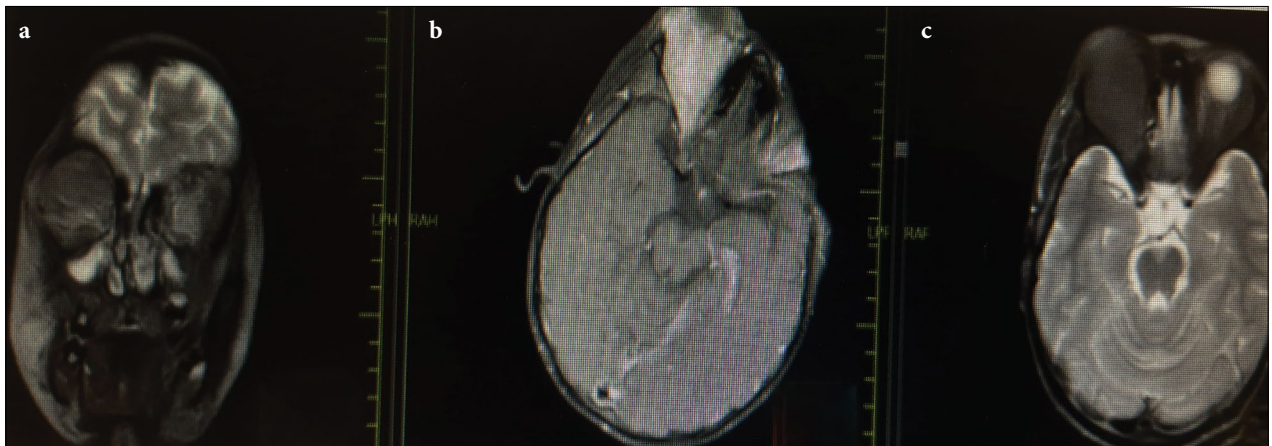
In the flow cytometric analysis performed on his bone marrow aspirate, myeloblasts comprised 14% of total events, expressing CD11b, CD13, CD15, CD33, and CD34. Cytogenetic studies detected t(8;21). Simultaneously, trucut biopsy was performed from the mass. A diagnosis of “Myeloid Sarcoma” was made based on histopathological and immunohistochemical findings. No burst was observed in the cerebrospinal fluid.

The patient was started on the AML-Berlin Frankfurt Münster 2019 chemotherapy protocol.[3] Proptosis in the eye gradually decreased over the course of chemotherapy. Figure 3 shows that the mass regressed on the 45<sup>th</sup> day of treatment. The patient was started on maintenance therapy 7 months ago. He is in remission at the 13<sup>th</sup> month of the start of treatment, and his follow-up and treatment continues (Fig. 4).

Received: May 15, 2022  
Accepted: November 20, 2022  
Online: November 30, 2022  
Accessible online at:  
www.onkder.org

Dr. Ayşe ÖZKAN KARAGENÇ  
Sağlık Bilimleri Üniversitesi,  
Başakşehir Çam ve Sakura Şehir Hastanesi,  
Çocuk Hematoloji ve Onkoloji Kliniği,  
İstanbul-Türkiye  
E-mail: ayseozkankaragenc@gmail.com

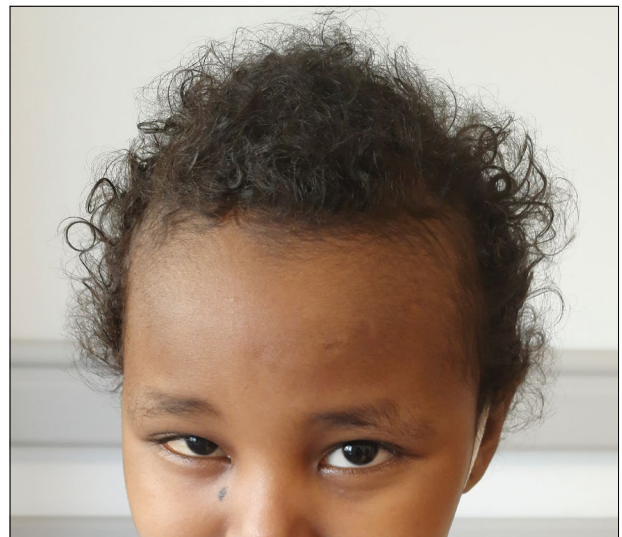



**Fig. 2 (a-c).** Coronal T2, axial T1, axial T2- weighted MRI images showing a 3.5×2×3.5 cm mass in the superior part of the right. MRI: Magnetic resonance imaging.



**Fig. 3.** The mass was largely resolved on the 45<sup>th</sup> day of treatment.



**Fig. 4.** The patient is in the 13<sup>th</sup> month of treatment and is in remission.

Myeloid sarcoma (granulocytic sarcoma, chloroma) occurs when myeloblasts or immature myeloid cells settle in the extra medullary space.[2] It is thought that myeloid sarcoma originates in the bone marrow and then cells spread through the Haversian ducts to penetrate the lower periosteum, followed by soft-tissue masses. This pathophysiology explains the typical location of lesions close to bone structures.[4]

MS; AML may occur together with myelodysplastic syndrome or chronic myelocytic leukemia, may be alone, or may be seen in disease recurrence.[5] In a literature review study, it was reported that 10% (n=25) of 243 orbital MS patients followed since 1978 had isolated MS. About 90% of these patients (n=218) have previous or simultaneous bone marrow involvement.[6]

The orbit is one of the most common localizations of MS in children. Orbital MS is most commonly as-

sociated with AML M2, M4, and M5 subtypes.[7] Our patient had AML M2 subtype. The most common symptom of orbital MS is unilateral exophthalmos, but lacrimal gland involvement, conjunctival mass, iridic, and diffuse uveal involvement can be seen, as well as retinal hemorrhages.[8]

Biopsy from the lesion remains the only method for the final diagnostic evaluation, especially in patients who develop isolated MS.

Even if myeloid sarcoma is an isolated lesion without bone marrow involvement, it should be treated with chemotherapy to prevent it from transforming into AML. In those left untreated, it usually turns into AML within a year.[9]

Radiotherapy is used as a palliative treatment to reduce the effects of tumor compression or the pain and itching associated with leukemia cutis. If the response to chemotherapy is not fully achieved, it can also be considered as consolidation therapy. If a specific complication such as obstruction or compression occurs depending on the localization of the tumor, surgical treatment is indicated.[5]

There are comparative data on the prognosis of the disease when MS is alone and associated with AML. Tsimberidou et al.[10] it has been shown that non-leukemic MS patients have a longer event-free survival compared to AML patients. Johnston et al.[11] compared the survival of patients with orbital MS, central nervous system MS, and those without extramedullary manifestations. In their studies, patients with orbital MS and central nervous system MS showed a better prognosis than patients without extramedullary manifestations, with overall survival of 92% and 73% to 50%, respectively. Patients with orbital MS also showed a significantly lower recurrence rate. Dusenbery et al.[12] Extramedullary involvement has been shown to be a favorable prognostic factor in pediatric patients with AML.

Orbital MS should be considered in the differential diagnosis of proptosis, it should be diagnosed quickly and treatment should be started. As in our patient, in many MS patients, there is a significant regression in the mass with only chemotherapy without the need for surgery and radiotherapy.

## REFERENCES

1. Fish JD, Lipton JM, Lanzkowsky P. Lanzkowsky's manual of pediatric hematology and oncology. 7<sup>th</sup> ed. Salt Lake City: Academic Press; 2021. p. 413–39.
2. Pizzo PA, Poplack DG. Principles and practice of pediatric oncology. 7<sup>th</sup> ed. Philadelphia: Lippincott Williams & Wilkins; 2015. p. 1135.
3. Reinhardt D, Dworzak M, Rasche M. Recommendations for diagnostics, therapy and follow-up care of children and adolescents with Acute Myeloid Leukemia (AML) 2019. V1.0\_19.07.2019.
4. Kapoor R, Khunger JM, Sharma A, Sachdeva S. The paradox of recurrent with rare: A rare case of bilateral proptosis and facial palsy in acute myeloid leukemia with recurrent cytogenetic translocation t(8:21). *Int J Appl Basic Med Res* 2015;5(1):76–8.
5. Samborska M, Derwich K, Skalska-Sadowska J, Kurzawa P, Wachowiak J. Myeloid sarcoma in children - diagnostic and therapeutic difficulties. *Contemp Oncol (Pozn)* 2016;20(6):444–8.
6. AlSemari MA, Perrotta M, Russo C, Alkatan HM, Maktabi A, Elkhamary S, et al. Orbital myeloid sarcoma (chloroma): Report of 2 cases and literature review. *Am J Ophthalmol Case Rep* 2020;19:100806.
7. Ohanian M, Faderl S, Ravandi F, Pemmaraju N, Garcia-Manero G, Cortes J, et al. Is acute myeloid leukemia a liquid tumor? *Int J Cancer* 2013;133(3):534–43.
8. Roby BB, Drehner D, Sidman JD. Granulocytic sarcoma of pediatric head and neck: An institutional experience. *Int J Pediatr Otorhinolaryngol* 2013;77(8):1364–6.
9. Yamauchi K, Yasuda M. Comparison in treatments of nonleukemic granulocytic sarcoma: Report of two cases and a review of 72 cases in the literature. *Cancer* 2002;94(6):1739–46.
10. Tsimberidou AM, Kantarjian HM, Wen S, Keating MJ, O'Brien S, Brandt M, et al. Myeloid sarcoma is associated with superior event-free survival and overall survival compared with acute myeloid leukemia. *Cancer* 2008;113(6):1370–8.
11. Johnston DL, Alonzo TA, Gerbing RB, Lange BJ, Woods WG. Superior outcome of pediatric acute myeloid leukemia patients with orbital and CNS myeloid sarcoma: A report from the Children's Oncology Group. *Pediatr Blood Cancer* 2012;58(4):519–24.
12. Dusenbery KE, Howells WB, Arthur DC, Alonzo T, Lee JW, Kobrinsky N, et al. Extramedullary leukemia in children with newly diagnosed acute myeloid leukemia: A report from the Children's Cancer Group. *J Pediatr Hematol Oncol* 2003;25(10):760–8.